

**DATE PRESENTING CLINICAL SIGNS**

3/17/2022

PATIENT

Leia Hines

Hematuria. 10/27/21 owner reported hematuria. UA showed hematuria and pyuria. Course of Amoxicillin dispensed. Recheck UA 11/27/21 showed hematuria, pyuria, moderate cocci and 3+ struvite. Owner declined diagnostics and Clavamox was dispensed. 12/23/21 UA showed that hematuria and pyuria had resolved, rare cocci and 2+ struvite present. Owner declined radiographs and urine culture as no clinical signs were present. 2/8/22 Owner seeing blood in urine and radiographs and culture were scheduled. Urine culture negative. Owner still seeing blood in urine, no stranguria present.

SPECIES

Canine

Current Medications: None.

Lab Results: See attached.

Radiographs: 3/3/22 Abdominal radiographs-no obvious calculi visible.

BREED

Mixed

Date of Previous IntraPet Ultrasound: No previous.

Sedation: Patient sedated with Dexdomitor.

Stat Report: Not requested.

SEX

Spayed Female

Imaging Performed By: Andi Parkinson, RDMS.

AGE

48.5lbs

ULTRASONOGRAPHIC EXAMINATION OF THE ABDOMEN**WEIGHT**

10/10/2015

Urinary System

The urinary bladder, trigone, and pelvic urethra are normal in thickness and the mucosal surface is smooth. The bladder lumen is moderately distended. A small amount of suspended echogenic debris is observed within the lumen. No masses, inflammatory changes or calculi are observed. Ureteral papillae and visualized portion of the proximal urethra, visible to a depth of 2 cm, are normal.

INTERPRETED BY

Andrea Nicastro, DMV,
Diplomate DACVIM
(Small Animal
Internal Medicine)

The left kidney is normal size (6.91 cm in length); normal shape and architecture with smooth peripheral margins. An ill-defined hyperechoic medullary band is observed at the corticomedullary junction. There is a normal 1:3 cortex to medulla ratio with mild to moderate loss of corticomedullary distinction. There is no evidence of pyelectasia, nephroliths, infarcts or hydronephrosis. Renal vasculature is normal.

HOSPITAL NAME

CityPets VC

The right kidney is normal size (7.70 cm in length); normal shape and architecture with smooth peripheral margins. An ill-defined hyperechoic medullary band is observed at the corticomedullary junction. There is a normal 1:3 cortex to medulla ratio with mild to moderate loss of corticomedullary distinction. There is no evidence of pyelectasia, nephroliths, infarcts or hydronephrosis. Renal vasculature is normal.

REFERRING VET

Dr. Shook

Adrenal Glands

The left adrenal gland is normal size (0.41 cm at cranial pole) (0.63 cm at caudal pole) (2.68 cm in length); normal shape. A 0.93 x 0.60 hyperechoic, to slightly heterogenous nodule is observed at the caudal pole. Glandular echogenicity and detail at the cranial pole are normal. The phrenicoabdominal vein and surrounding vasculature are normal.

INVOICE

10570

The right adrenal gland is normal size (0.54 cm at cranial pole) (0.56 cm at caudal pole) (2.54 cm in length); normal shape; homogenous parenchyma. The glandular echogenicity and detail are unremarkable. Capsule, cortex, and medullary definition are normal. The phrenicoabdominal vein and surrounding vasculature are normal.

Spleen

The spleen is normal in size (1.78 cm in width at the level of the hilus) with a normal capsular contour. There is appropriate echogenicity and echotexture. A 1.29 cm irregular hypoechoic to anechoic nodule is observed at the medial aspect near the hilus. In addition, an ill-defined 1.56 cm hypoechoic nodule is also seen at the medial aspect. Splenic vasculature is normal.

Liver

The liver is subjectively normal in size with normal contours and structure. There is appropriate echogenicity and echotexture. No overt structural evidence of inflammatory, infiltrative, or regenerative pathology is evident. Vascular and biliary tracts are of normal volume with no evidence of congestion. No pathological hepatic lymphadenopathy observed.

The gall bladder lumen is moderately distended. The wall is thin and smooth. A small to moderate amount of mostly gravity dependent, echogenic debris is observed within the lumen. . The cystic and common bile ducts are normal.

Gastrointestinal

The gastric lumen is not distended. The gastric wall is normal in thickness with a normal layering pattern. The small intestinal lumen is not dilated. The small intestinal wall thickness is normal with a normal layering pattern and appropriate mural detail. Discreet masses are not identified. The colonic wall is normal. No obstructive or overt infiltrative disease is noted.

Pancreas

The region of the pancreas is isoechoic relative to surrounding omental fat. No obvious parenchymal abnormalities are observed. There is no evidence of regional inflammation or effusion.

Free Abdomen

The peritoneal cavity is normal. There is no evidence of inflammation or effusion. The abdominal lymph nodes are normal/not visible.

ULTRASONOGRAPHIC FINDINGS

Primary Findings

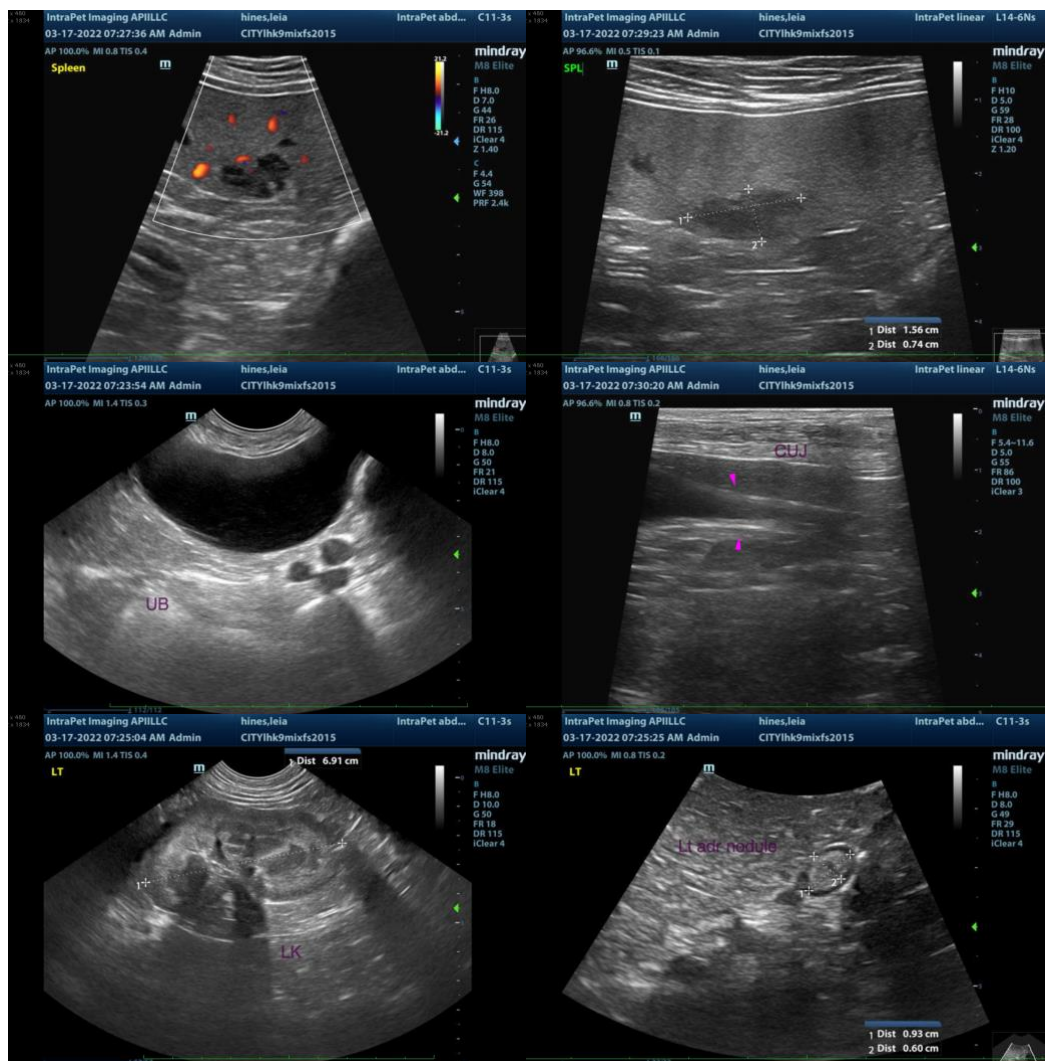
- Bilateral nonspecific, chronic age-related renal changes.
- The splenic nodules could be consistent with emerging neoplasia or a benign process (i.e., foci of extramedullary hematopoiesis or lymphoid hyperplasia).
- The left adrenal nodule trends toward the benign (i.e., nodular hyperplasia), with some potential for emerging neoplasia.
- Urinary bladder debris

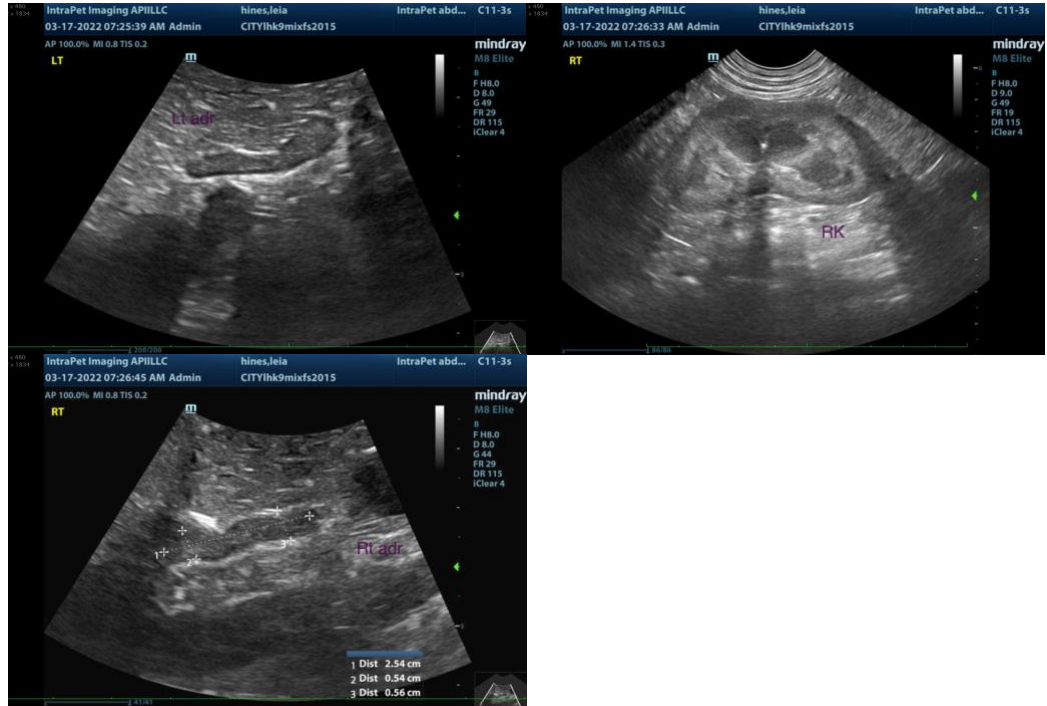
**An obvious cause for the patient's hematuria is not identified in this study. Considerations include occult pyelonephritis, benign essential renal hematuria, coagulopathy, other.

INTERPRETATION OF THE FINDINGS & FURTHER RECOMMENDATIONS

- Baseline lab work, including a CBC Chemistry panel and T4 +/- PT/PTT, is recommended, if not already performed.

- Despite the negative urine culture, consider empirical treatment for occult pyelonephritis (i.e., fluoroquinolone). If there is no improvement in the hematuria within 5-7 days of initiating therapy, antibiotics should be discontinued
- If the hematuria persists and diagnostics are inconclusive, benign essential renal hematuria may be present the patient's PCV should be monitored for the development of anemia.





The information and recommendations provided are based on the images presented by the referring veterinarian/sonographer. No evaluation can be communicated regarding pathology that was not visible in the image/video clips provided.

Thank you for this referral. If the clinical or image interpretation does not parallel your findings or if I can be of any further assistance, please contact me.

Andrea Nicastro, DVM, Diplomate DACVIM (Small Animal Internal Medicine)
info@SonoPath.com